

TOXICITY OF FLUORIDE IN CATTLE OF THE INDIAN THAR DESERT, RAJASTHAN, INDIA

SL Choubisa,^a Vikas Modasiya,^b CK Bahura,^b Zulfiya Sheikh^c
Udaipur and Bikaner, India

SUMMARY: Chronic toxic effects of fluoride (F) in the form of osteo-dental and nonskeletal fluorosis were observed in 99 domesticated cattle (*Bos taurus*) living in Chani village, Bikaner district of Rajasthan state (India), located in the Indian Thar Desert. F in drinking water sources (bore wells) of this village varies between 1.5 and 2.5 ppm (mean 2.0 ppm). Out of 24 calves (<2 years age) and 75 cows (>3 years age), 10 (41.7%) and 28 (37.3%), respectively, exhibited mild to severe dental mottling. Their anterior teeth were bilaterally striated, and horizontally had light to deep yellowish in colour. In some calves, dental staining was found to be light brown to deep brownish or dark. In severe forms of dental fluorosis, irregular wearing of teeth and recession and swelling of gingiva were also present. In older cows pronounced loss of teeth supporting alveolar bone with recession and bulging gingiva, and exposed cementum of incisor roots were more common. Eight of the calves (33.3%) and 30 of the cows (40.0%) exhibiting dental fluorosis also revealed signs of skeletal fluorosis as intermittent lameness and snapping sound in legs, wasting of body muscles, and excessive periosteal exostoses in the mandibles, ribs, metacarpus, and metatarsus regions. In these animals, colic, intermittent diarrhoea, excessive urination, irregular reproductive cycles, repeated abortions, and stillbirths were also found as signs of nonskeletal fluorosis. To the best of our knowledge, *toxic effects of chronic fluoride exposure in any species of domestic animals of the Indian Thar Desert have not been reported previously.*

Keywords: Cattle (*Bos taurus*); Fluoride toxicity; Indian Thar Desert; Osteo-dental fluorosis; Nonskeletal fluorosis; Rajasthan; India.

INTRODUCTION

Chronic exposure to fluoride (F) in groundwater causes adverse health problems not only in humans, but also in various species of domestic animals in the form of fluorosis. The primary manifestations are mottling of teeth (dental fluorosis), and osteosclerosis of the skeleton (skeletal fluorosis). Besides these maladies, nonskeletal fluorosis or toxic effects of chronic fluoride exposure in soft tissues, viz., gastrointestinal discomforts, neurological disorders, impaired endocrine and reproductive functions, teratogenic effects, apoptosis, genotoxic effects, excitotoxicity, etc., have also been reported in man as well as in domestic and laboratory animals. These effects have also been reviewed recently.¹

The prevalence, and severity of fluorosis is well known to be affected by various factors.^{2,3} Besides the duration of F exposure, its concentration, and individual biological responses or tolerance, environmental factors also influence the toxicity of F in animals.⁴⁻⁶

The present study deals with the state of Rajasthan in India, which is divided into two distinct geographical regions by the Aravali mountain range. In the Northwest region a perfect desert environment exists where drinking water of

^{a,c}For correspondence: Dr SL Choubisa, Associate Professor and Head, Post Graduate Department of Zoology, Government Meera Girls College, Udaipur-313001, India; E-mail: choubisasl@yahoo.com; ^bPost Graduate Department of Zoology, Government Dungar College, Bikaner 334001, India; E-mail: cbahura@gmail.com; zoology.vikas@gmail.com.

animals contains very high levels of F ranging between 12.0 and 90.0 ppm.⁷ In the other part, i.e., in Southeastern Rajasthan, where a semi-arid or humid ecosystem persists, a relatively lower range of F (1.44 to 28.1 ppm) in groundwater has been reported.⁷ In the humid region, toxic effects of fluoride in cattle (*Bos taurus*), buffaloes (*Bubalus bubalis*), sheep (*Ovis aries*), goats (*Capra hircus*), camels (*Camelus dromedarius*), horses (*Equus caballus*), and donkeys (*E. asinus*) have been studied in areas with different concentrations of groundwater F.^{8–10} Although the desert region has a different environment containing a relatively high amount of F in the drinking water, so far as we are aware, no study of F toxicosis in any species of domestic animals has been conducted in that region. The present pilot investigation of chronic fluorosis in cattle was undertaken and conducted in Chani village of the Indian Thar Desert located in this area of Rajasthan.

MATERIALS AND METHODS

Study area: The Chani village in Kolayat Tehsil of the Bikaner district in the Indian Thar Desert of Rajasthan was selected for the present pilot study. Rajasthan⁷ is the largest state of India, lying between 23°3' and 30°12' N latitude and 69°30' and 78°17' E longitude with its 342,239 km² being 10.4% of the area of the country (Figure 1) and, as noted in the introduction, is geographically divided by the Aravali range into two distinct regions (Figure 2). The two regions are

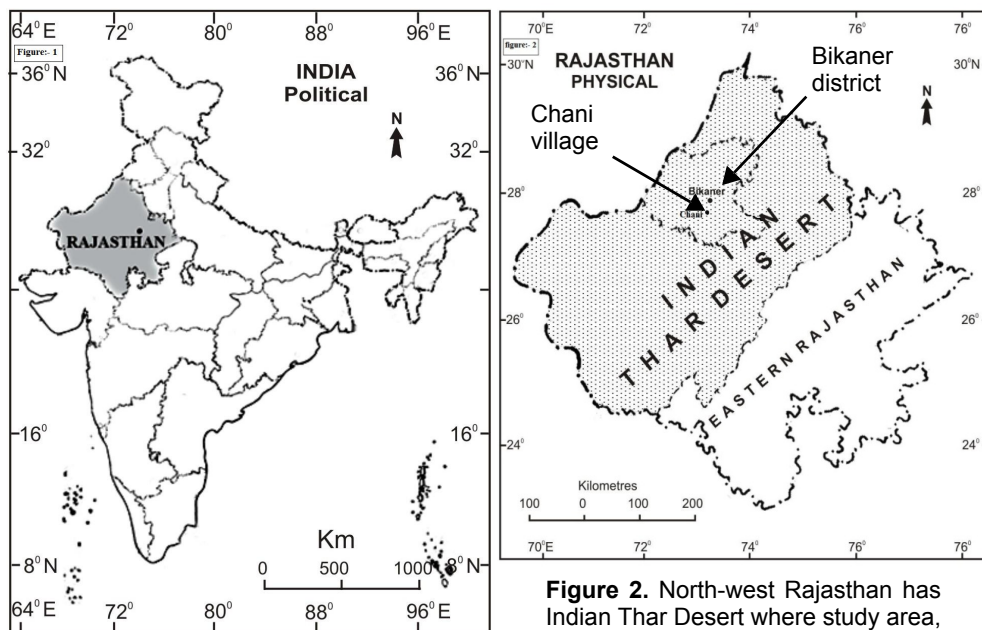


Figure 1. Rajasthan is the largest state of India where ground/drinking water contains fluoride in almost all districts.

Figure 2. North-west Rajasthan has Indian Thar Desert where study area, Chani village is located in Bikaner district.

ecologically different having their own kind of environments. The Northwest part of Rajasthan contains the major portion of the Indian Thar Desert, covering an area of approximately 200,000 km². The region has a typical arid and hot climate with low and irregular rainfall. In general, the annual rainfall is in the range of 260–440 mm, and the temperature ranges from 1°C to 48°C.

Drinking water sources and F analysis: In the Chani village the drinking water sources for domestic animals are bore wells. The water samples from these sources were collected in polythene bags and brought to the laboratory. The F concentration of the samples was estimated spectrophotometrically using an alizarin method employed earlier.^{11,12} It varied from 1.5 to 2.5 ppm (mean 2.0 ppm) against the maximum permissible limit of 1.5 ppm; but pH, total hardness, and alkalinity were within the permissible limits.

Survey and identification of fluorosis: House-to-house surveys were made in the early morning and late evening when the animals were generally available and in herds in the field during day-time to obtain estimates of the prevalence and severity of F toxicity in the form of osteo-dental fluorosis in mature and immature cattle. Only native cattle that had been in the village from birth were surveyed. For evidence of dental fluorosis, anterior teeth of animals were observed for dental mottling or staining. For skeletal fluorosis, poor body condition, lameness, reluctance to move or stiffness, skeletal deformities, bony exostosis, muscle wasting, and a snapping sound from the feet during walking were looked for.^{13,14} Cattle owners were also asked about common complaints such as colic, diarrhoea, constipation, bloating, urticaria, emaciation, estrous cycle, abortion, still birth, etc. F concentrations in blood plasma and urine were not determined; data on fluorosis were based only on clinical findings.

OBSERVATIONS AND DISCUSSION

Dental fluorosis: Out of 24 calves and 75 cows, 10 calves (41.7%), and 28 cows (37.3%) exhibited various grades of fluorotic dental mottling. Their anterior teeth were bilaterally striated and were horizontally light to deep yellowish in colour (Figures 3–5).

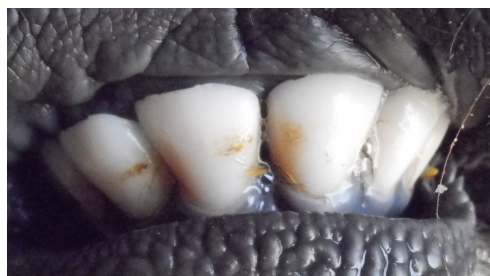

Figure 3. Mild form of dental fluorosis in a calf.

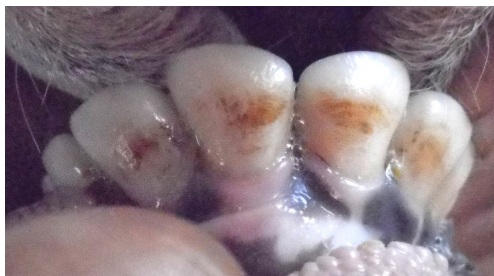


Figure 4. Moderate form of dental fluorosis in a calf.

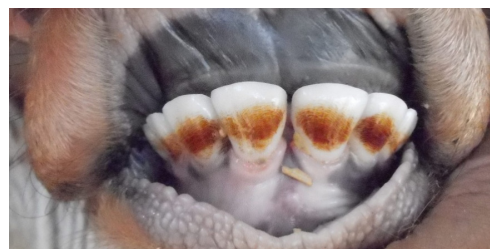

Figure 5. Severe form of dental fluorosis (deep yellowish coloration) in a calf.

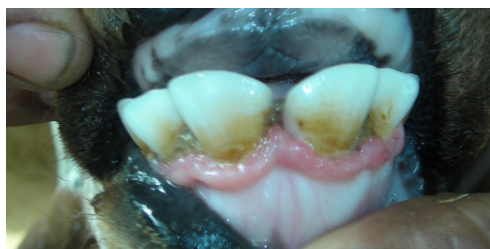

Figure 6. Mild form of dental fluorosis in a calf.

In some calves, the dental staining was light brown to deep brownish or black (Figures 6–8). Generally, the staining in calves was more condensed, well stratified, and homogeneous, but in older cows it appeared in mosaic form. In severe form, irregular wearing of teeth and recession and swelling of gingiva were also observed. In older cows pronounced loss of tooth supporting alveolar bone with recession and bulging of gingiva and exposed cementum of incisor roots were common. Overall, the severity of dental mottling was more progressive with advancing age in the cattle.

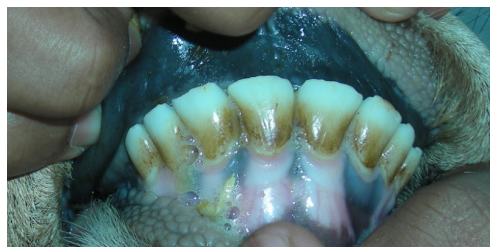

Figure 7. Moderate form of dental fluorosis in a calf.

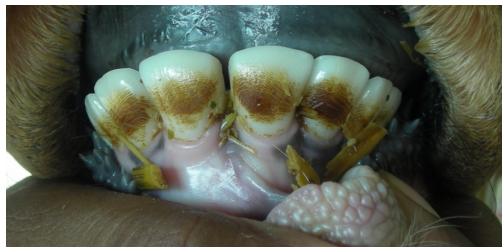

Figure 8. Severe form of dental fluorosis (deep brownish coloration) in a calf.

Skeletal fluorosis: Eight (33.3%) of the 24 calves and 30 (40.0%) of the 75 cows showed evidence of skeletal fluorosis. On careful examination and palpation of mandibular, scapular, tarsal, metatarsal, carpal, and cage regions of these animals, diffused to well-marked bony outgrowths (periosteal exostoses) were apparent (Figures 9–10). These animals were physically weak, indolent, and reluctant to move or stand. In these animals, mild to severe intermittent lameness and snapping sounds, especially in the hind legs, stiffness of leg tendons, and wasting of main mass of hind quarters and shoulder muscles were also observed.

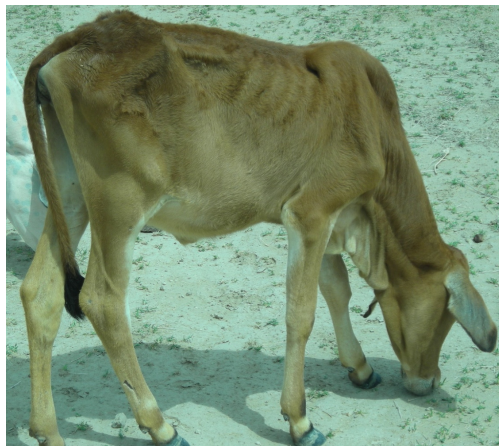

Figure 9. Emaciated <2-year-old calf afflicted with moderate skeletal fluorosis.



Figure 10. Emaciated <2-year-old calf afflicted with severe skeletal fluorosis. Note wasting of body muscles and bulging lesions on legs.

Other symptoms: According to the information given by the cattle owners and veterinarians, other signs of chronic F intoxication such as intermittent diarrhoea, colic, urticaria, and bloating were also present in the fluorosed animals. Among the cows, repeated abortions, stillbirths, and irregular estrous cycle were also

prevalent. Many of these cows had not conceived after several attempts at copulation or artificial insemination. Interestingly, none of the cattle owners and veterinarians were aware that these toxic effects can be caused by F in drinking water.

It is noteworthy that the pathognomic signs of dental fluorosis in calves and cows of the Indian Thar Desert are similar to those reported in bovines of the semi-arid or humid ecosystem of Southeast Rajasthan^{4,5,15,16} and in other parts of India.¹⁷⁻²⁰ Some calves in the present study had light brown to deep brownish dental staining instead of light to deep yellowish staining. This observation has also been reported previously in a few mature and immature buffalo in non-desert areas.⁵ The reason for such differences in dental staining is not clear, although the influence of certain minerals in the water and/or food may be involved.

The prevalence and severity of fluorotoxicosis in both man and animals varies greatly from place to place and region to region, even in areas with similar concentrations of F in the drinking water. Numerous determinants appear to be responsible for variations in F toxicity.²¹⁻²³ Among the cattle in the present study area, both the prevalence and severity of osteo-dental fluorosis were comparatively very high in association with a relatively low F concentration (2.0 ppm) in the drinking water. This fact indicates that, besides the F concentration, the desert environment/ecosystem also has a significant role in increasing the prevalence and severity of F toxicosis. Indeed, cattle are neither desert animals nor are they adapted physiologically and anatomically to that environment. Therefore, perspiration through body surface of cattle is definitely higher as compared to perfectly adapted desert animals, e.g., camels.²⁴ Moreover, the water loss through urine is more in cattle than in camels, since camels excrete more concentrated urine, an adaptation for arid ecosystem. To compensate for this physiological loss of water, cattle drink water more frequently. Therefore, their intake frequency of water increases which in turn leads to excess F toxicity in them.

This interpretation is further supported by the evidence of severe skeletal fluorosis in some of the calves (excessive periosteal exostoses) in the Chani village survey area. *The present study is important in that it reports, for the first time in India, evidence of fluoride toxicities in cattle living in the Indian Thar Desert of Rajasthan.* These findings can also be seen as contributing significantly to our existing knowledge of fluorosis. The provision of defluoridated drinking water, and health education aimed at abating fluorosis in animals is highly desirable in this desert area of Rajasthan.

ACKNOWLEDGEMENTS

The authors are sincerely thankful to the cattle owners/villagers, teachers, and school students for cooperation during examination of animals and also to Dr Kanan Saxena, Associate Professor of Zoology, and VJ Jaroli, Research Assistant, Post Graduate Department of Zoology, Government Meera Girls College, Udaipur, for support in preparation of the manuscript.

REFERENCES

- 1 Choubisa SL. Status of fluorosis in animals. Proc Natl Acad Sci India Sect B Biol Sci 2012;82(3):331-9.
- 2 Udall, DH. The practice of veterinary medicine. 5th ed. Menasha, WI, USA: George Banta Publishing Company;1954. pp 774-86.
- 3 Suttie, JW. Nutritional aspects of fluoride toxicosis. J Anim Sci 1980;51:759-66.
- 4 Choubisa SL. Chronic fluoride intoxication (fluorosis) in tribes and their domestic animals. Int J Environ Stud 1999;56(5):703-16.
- 5 Choubisa SL. Some observations on endemic fluorosis in domestic animals of Southern Rajasthan, India. Vet Res Commun 1999;23(7):457-65.
- 6 Choubisa SL. Fluoridated ground water and its toxic effects on domesticated animals residing in rural tribal areas of Rajasthan (India). Int J Environ Stud 2007;64(2):151-9.
- 7 Choubisa SL, Choubisa L, Choubisa DK. Endemic fluorosis in Rajasthan. Indian J Environ Health 2001;43(4):177-89.
- 8 Choubisa SL, Mishra GV, Sheikh Z, Bhardwaj B, Mali P, Jaroli VJ. Toxic effects of fluoride in domestic animals. Adv Pharmacol Toxicol 2011;12(2):29-37.
- 9 Choubisa SL. Osteo-dental fluorosis in domestic horses and donkeys in Rajasthan, India. Fluoride 2010;43(1):5-12.
- 10 Choubisa SL. Fluorosis in dromedary camels in Rajasthan, India. Fluoride 2010;43(3):194-9.
- 11 Choubisa SL, Sompura K, Choubisa DK, Pandya H, Bhatt SK, Sharma OP, et al. Fluoride content in domestic water sources of Dungarpur district of Rajasthan. Indian J Environ Hlth 1995;37(3):154-60.
- 12 Choubisa SL, Sompura K, Bhatt SK, Choubisa DK, Pandya H, Sharma OP. Fluoride in drinking water sources of Udaipur (Rajasthan). Indian J Environ Hlth 1996;38(4):286-91.
- 13 Shupe, JL. Clinicopathological features of fluoride toxicosis in cattle. J Anim Sci 1980;51:746-58.
- 14 Singh JL, Swarup D, Dogra RKS, Singh GR. Fluorosis in dairy cows: Clinicopathological findings. Indian J Anim Sci 1995;65(2):162-5.
- 15 Choubisa SL, Pandya H, Choubisa DK, Sharma OP, Bhatt SK, Sompura K, et al. Osteo-dental fluorosis in bovines of tribal region in Dungarpur (Rajasthan). J Environ Biol 1996;17(2):85-92.
- 16 Patra RC, Dwivedi SK, Bhardwaj B, Swarup D. Industrial fluorosis in cattle and buffalo around Udaipur, India. Sci Total Environ 2000;253:145-50.
- 17 Swarup D, Singh YP. Bovine fluorosis in a brick kiln congested zone. Indian J Vet Med 1989;9:12-14.
- 18 Swarup D, Dwivedi SK, Dey S, Ray SK. Fluoride intoxication in bovines due to industrial pollution. Indian J Anim Sci 1998;68:605-61.
- 19 Singh JL, Swarup D. Fluorosis in buffaloes. Vet Rec 1994;135:260-61.
- 20 Singh JL, Swarup D. Clinical observations and diagnosis of fluorosis in dairy cows and buffaloes: case study. Agri-Practice 1995;16:25-30.
- 21 Choubisa SL, Choubisa L, Choubisa D. Osteo-dental fluorosis in relation to nutritional status, living habits, and occupation in rural tribal areas of Rajasthan, India. Fluoride 2009;42(3):210-15.
- 22 Choubisa SL, Mishra GV, Sheikh Z, Bhardwaj B, Mali P, Jaroli VJ. Food, fluoride, and fluorosis in domestic ruminants in the Dungarpur district of Rajasthan, India. Fluoride 2011;44(2):70-76.
- 23 Choubisa SL. Osteo-dental fluorosis in relation to chemical constituents of drinking waters. J Environ Sci Eng 2012;54(1):153-8.
- 24 Bornstein S. The ship of the desert. The dromedary camel (*Camelus dromedarius*), a domesticated animal species well adapted to extreme conditions of aridness and heat. Rangifer 1990;Special issue 3:231-6.